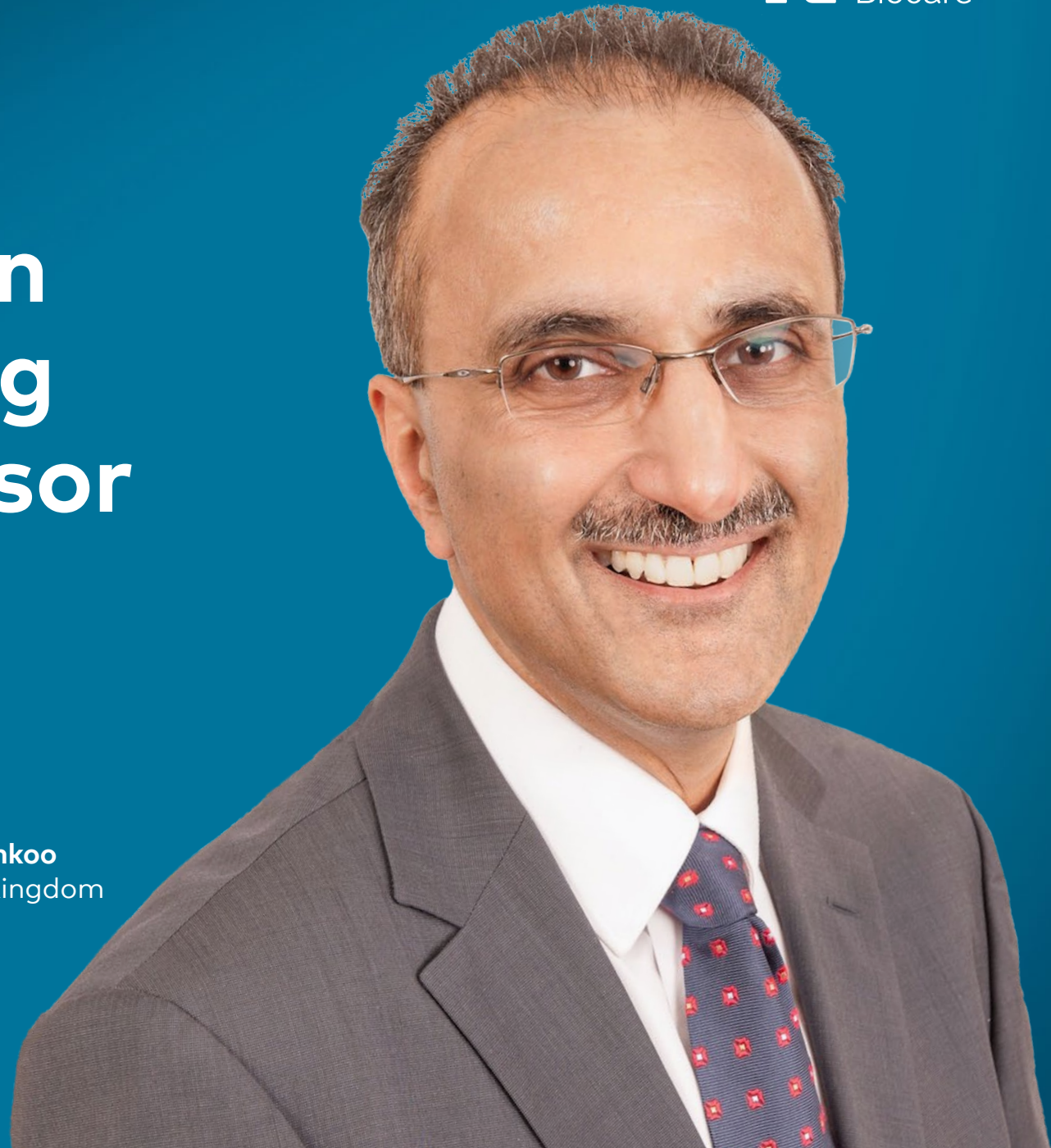

CLINICAL CASE



Restoration of a missing lateral incisor

Tidu Mankoo
United Kingdom





Tidu Mankoo



Dental technicians Luc & Patrick Rutten



Case description

Restoration of a missing lateral incisor

Patient

22 years, male

Clinical situation

Congenitally missing right lateral and peg shaped left lateral maxillary incisor

Surgical solution

Extraction & immediate placement of NobelActive® TiUltra™ implant

Restorative solution

Temporary: SnapTemp abutment and Tempshell crown
Final: NobelProcera® ASC Full Contour Zirconia Implant Crown

Surgery date(s)

April, 2019

Total treatment time

3 months

Tooth position(s)


12

Patient with congenitally missing right and peg-shaped left lateral incisor.

Orthodontic treatment was carried out to align the teeth and create the correct space for restoration of both lateral incisors.

The maxillary left incisor was restored with a lithium disilicate veneer followed by extraction of right deciduous lateral incisor with immediate placement of a NobelActive® TiUltra™ implant and immediate provisionalisation.

Simultaneous soft tissue augmentation was carried out with sub-epithelial connective tissue graft.



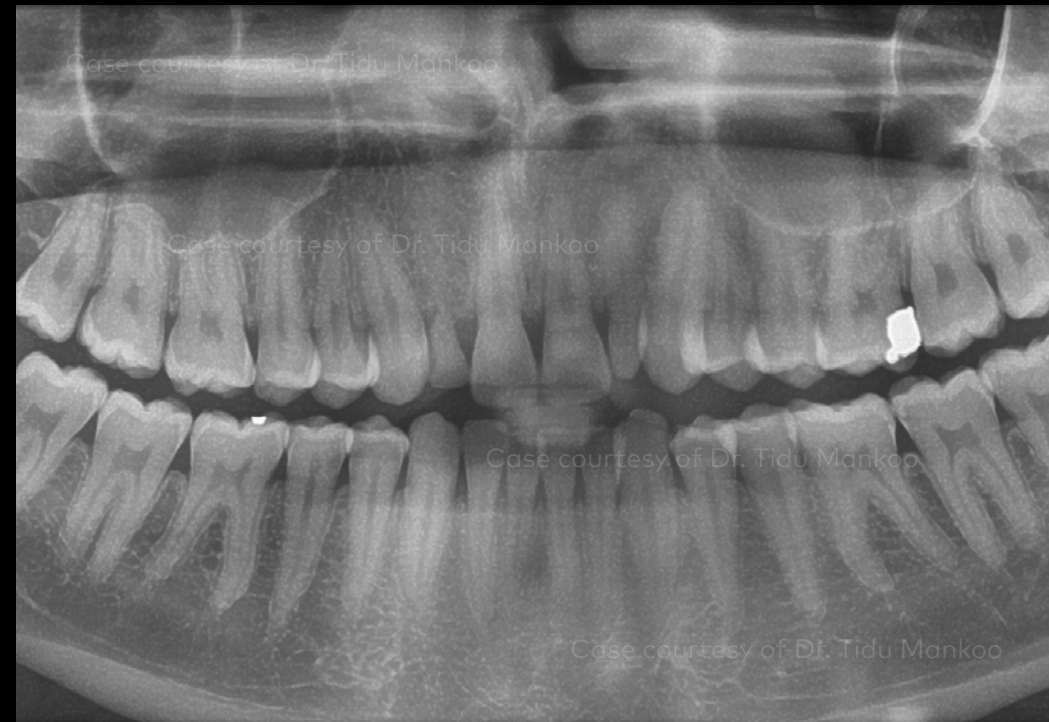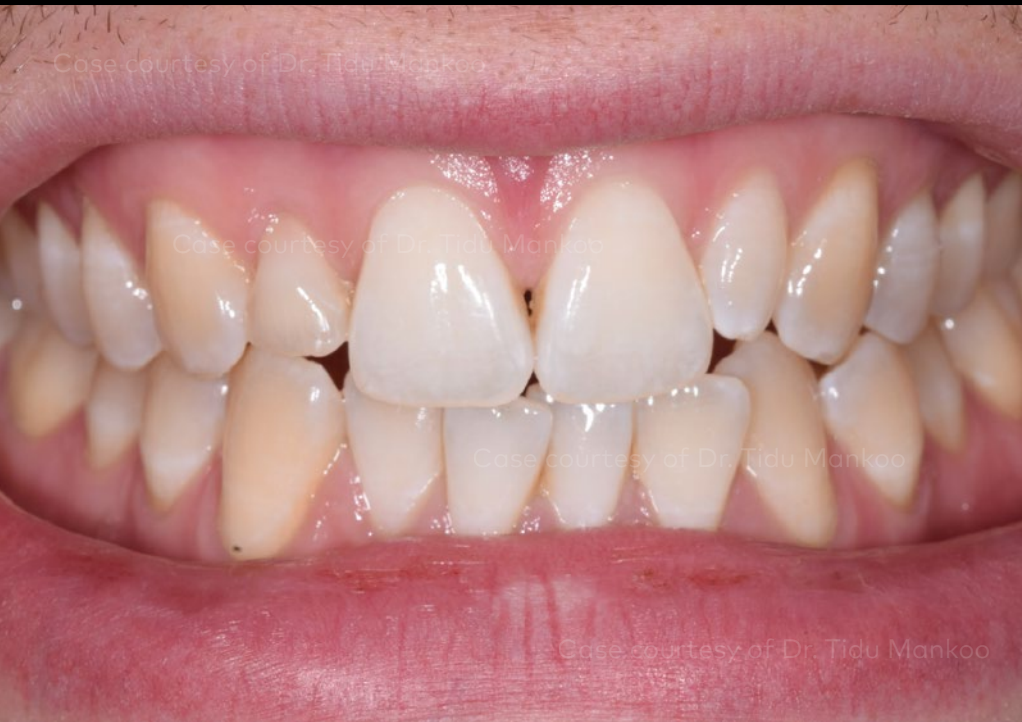Initial clinical situation

Treatment planning

Surgical procedure

Restorative procedure

Outcome



Clinical view of patient with retained deciduous right maxillary lateral incisor and peg-shaped left lateral. Note the poor relative proportions of the incisors, anterior crowding and the lack of adequate space for the maxillary lateral incisors.

Apical root resorption of the retained right lateral incisor.

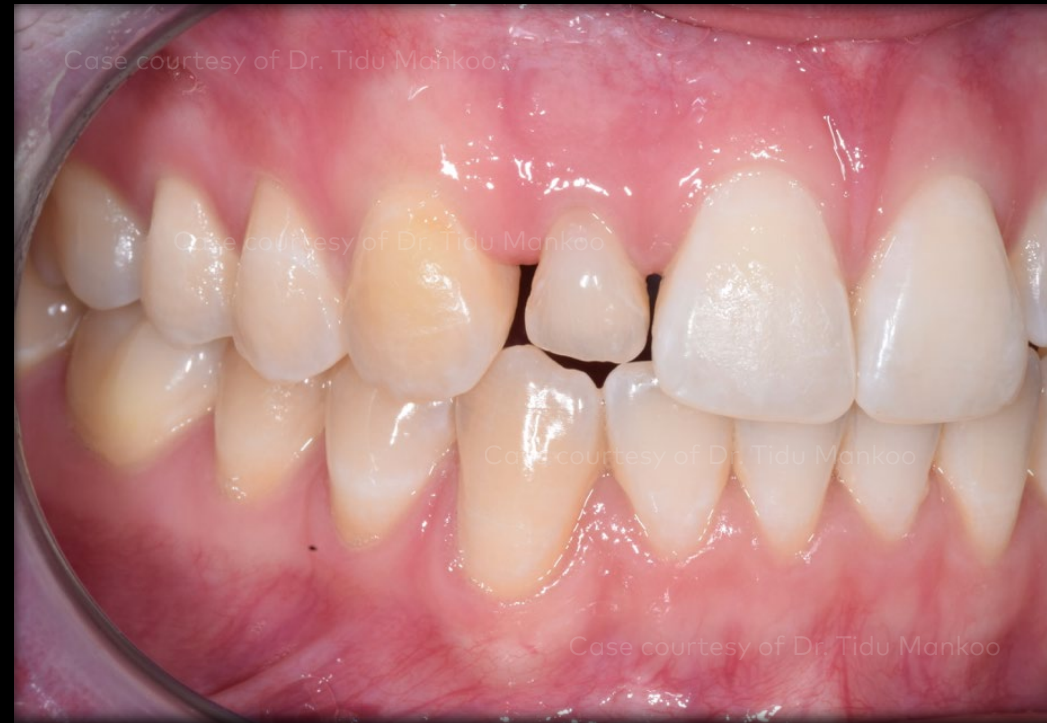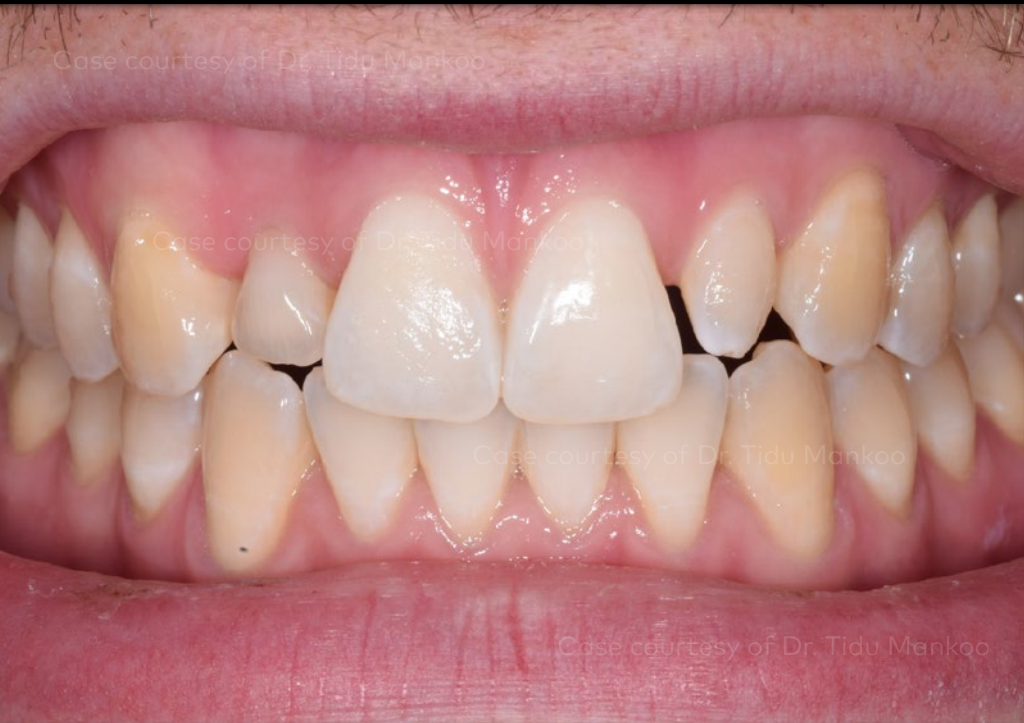Initial clinical situation

Treatment planning

Surgical procedure

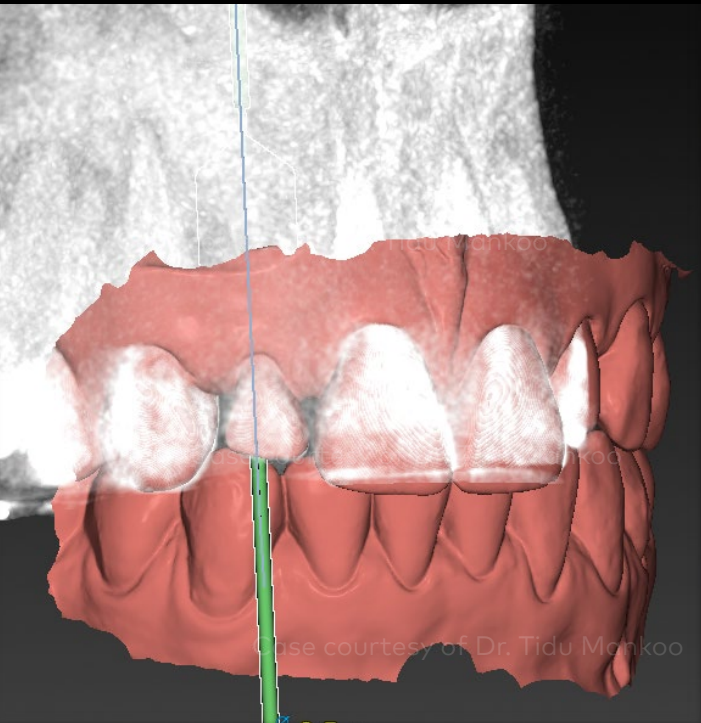
Restorative procedure

Outcome

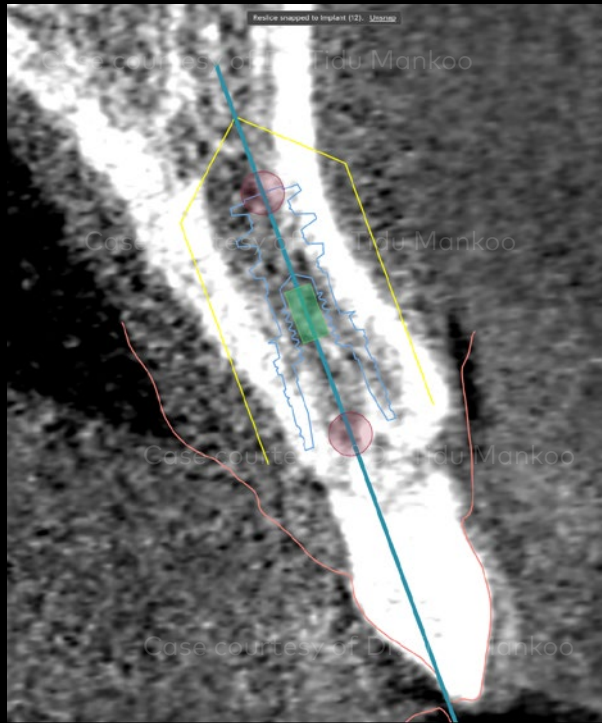


Clinical situation after 14 months of orthodontic treatment.

Initial clinical situation



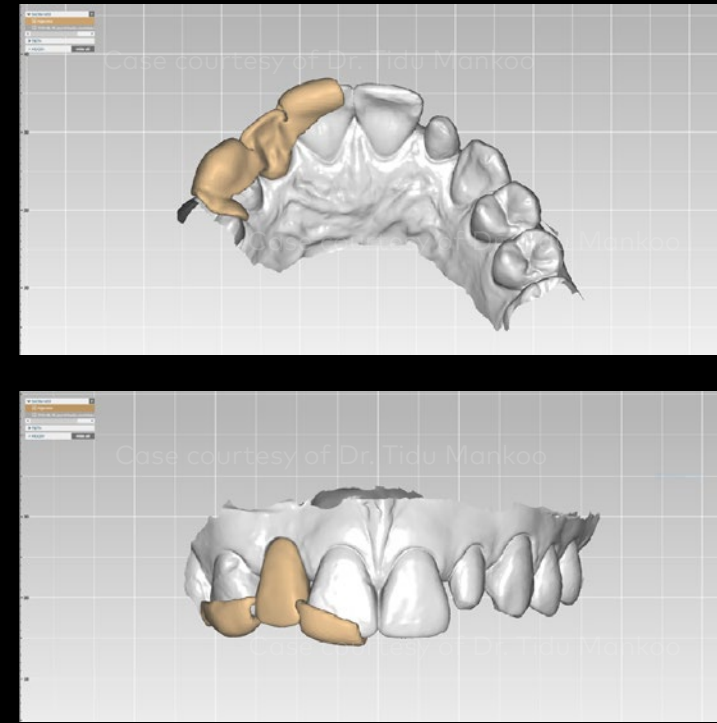
Treatment planning



Surgical procedure

Restorative procedure

Outcome



Digital planning of the implant placement and digitally designed TempShell in the DTX Studio™ Implant software.

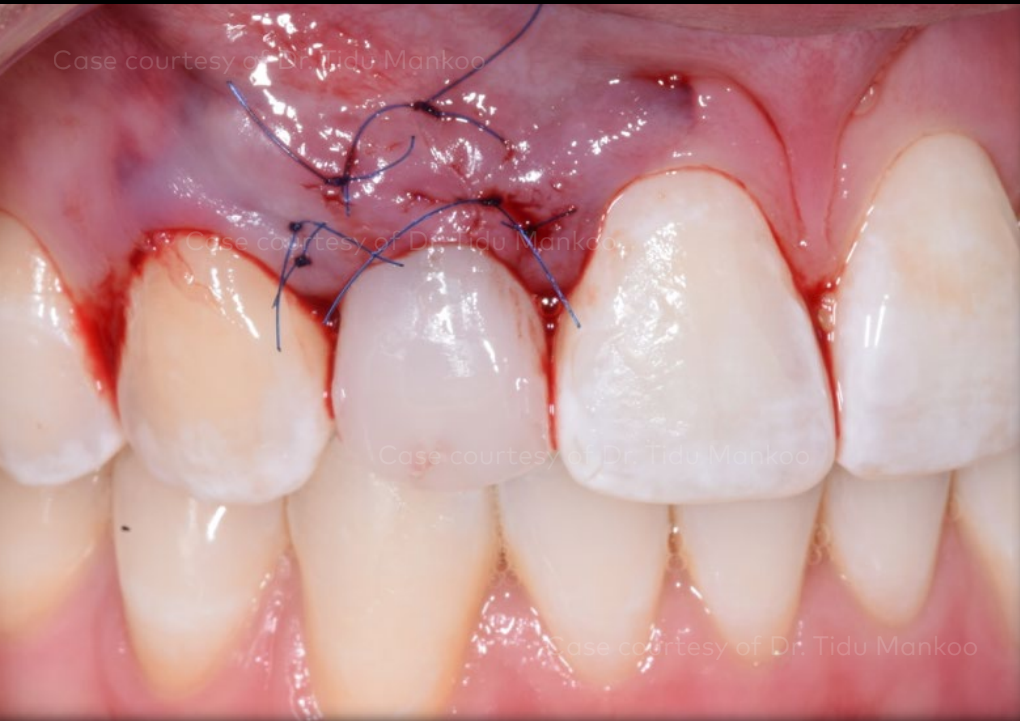Initial clinical situation

Treatment planning

Surgical procedure

Restorative procedure

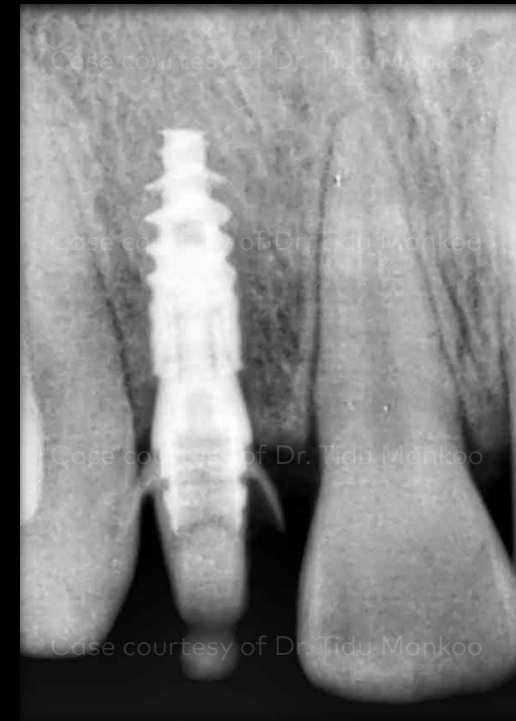Outcome



Immediate postoperative situation with temporary crown in place on a 3mm SnapTemp abutment and a connective tissue graft to augment labial volume.



NobelActive® TiUltra™ 3.5 x 10 mm implant.



Radiograph of the NobelActive® TiUltra™ implant with the SnapTemp abutment right after the surgery.

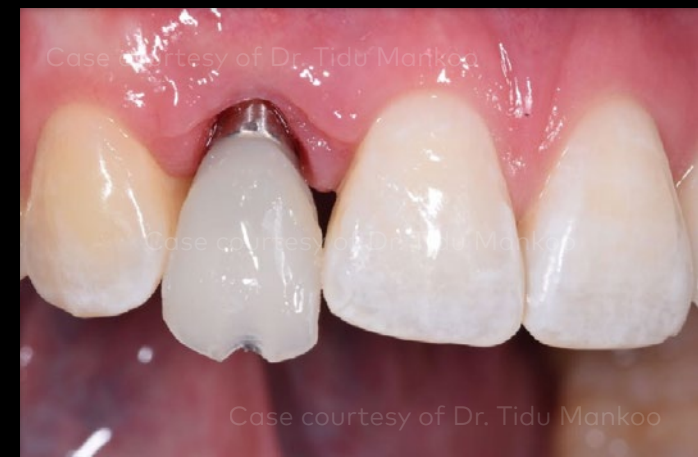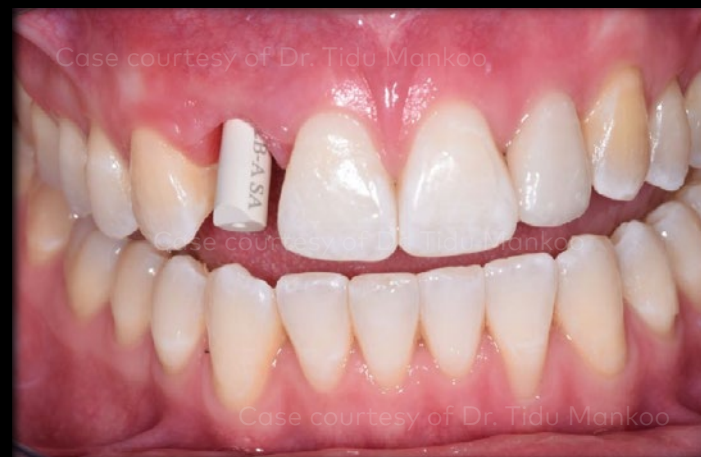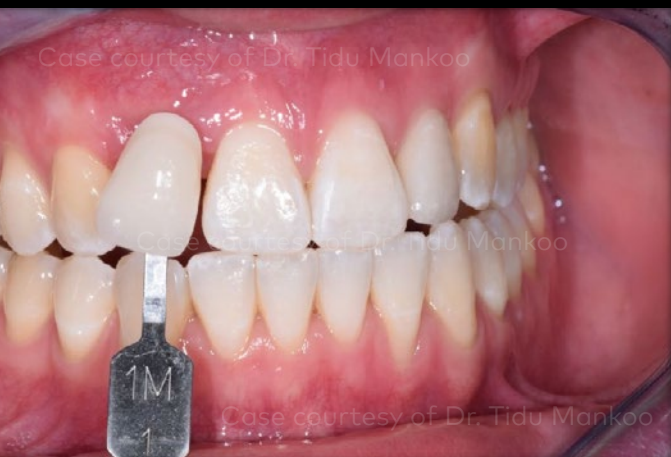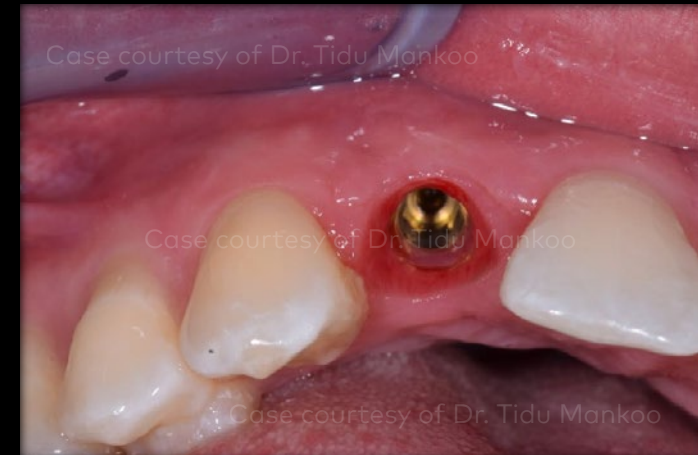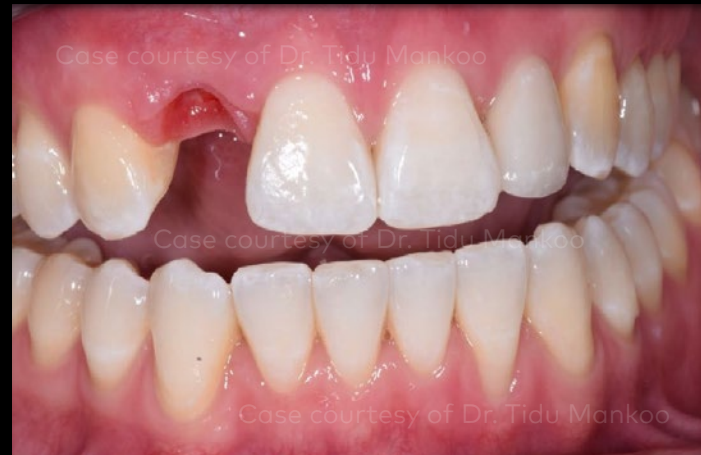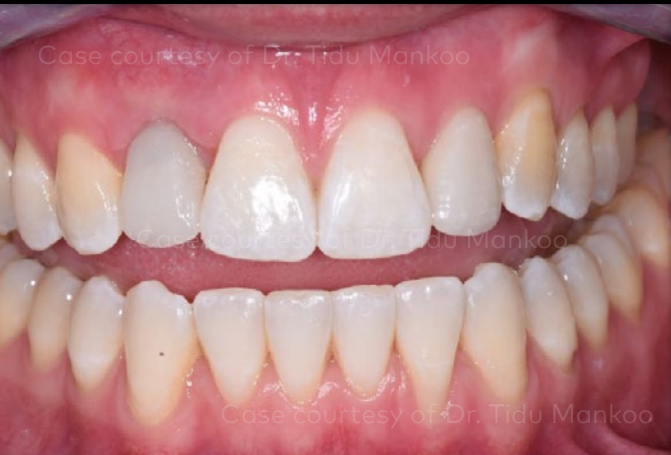Initial clinical situation

Treatment planning

Surgical procedure

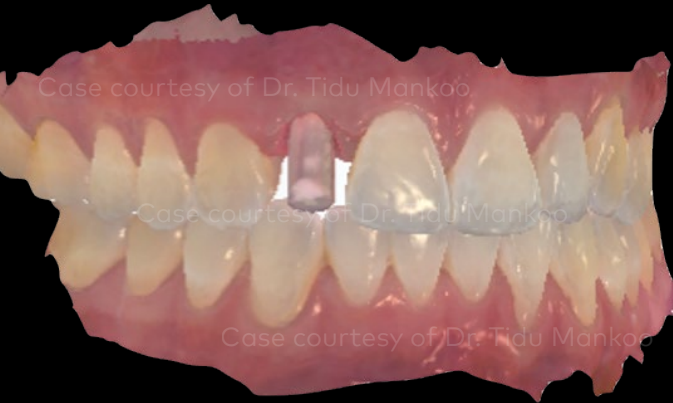Restorative procedure

Outcome

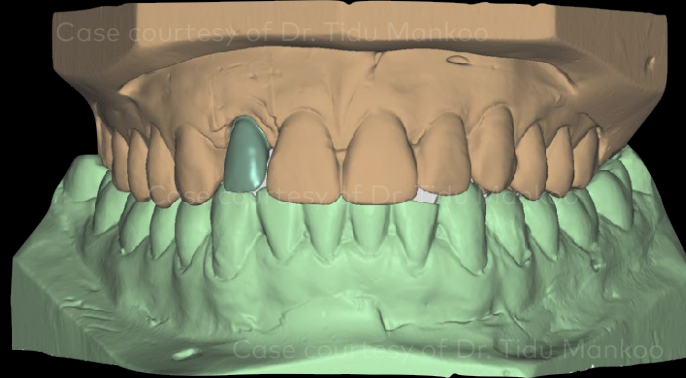


At 2 months, impressions were taken (both conventional and digital) and shade communication provided to the laboratory. The temporary was refitted.

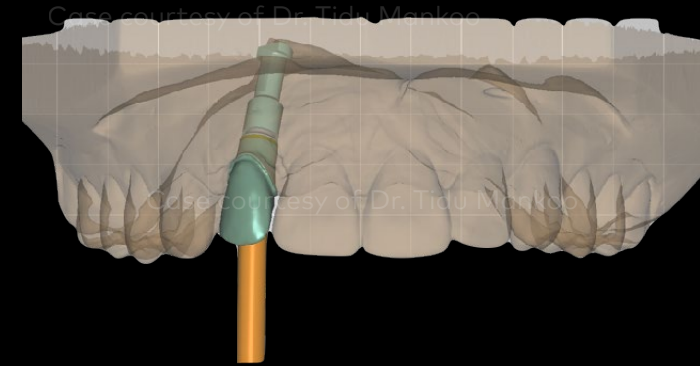
Initial clinical situation



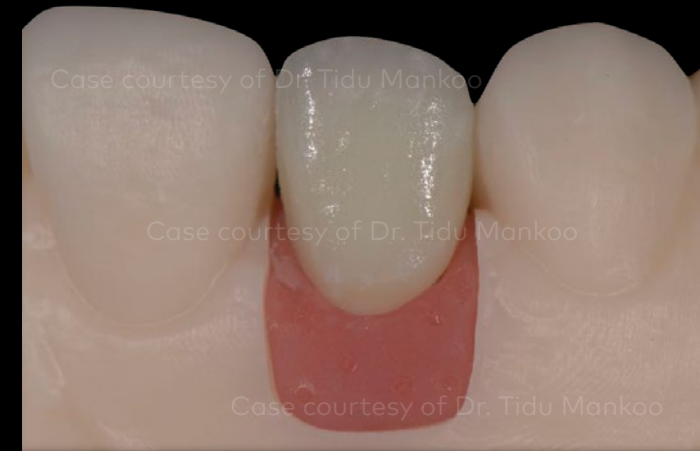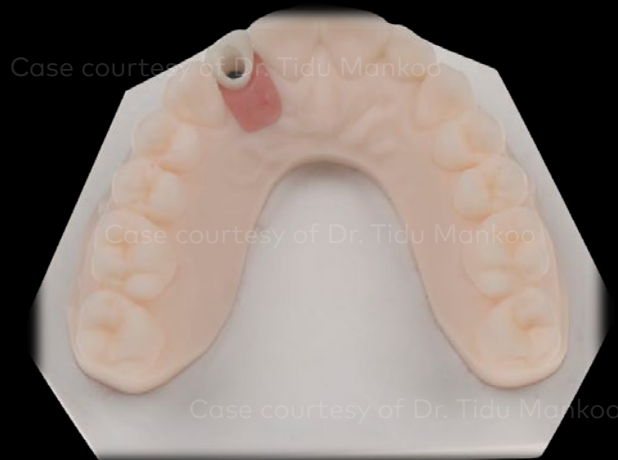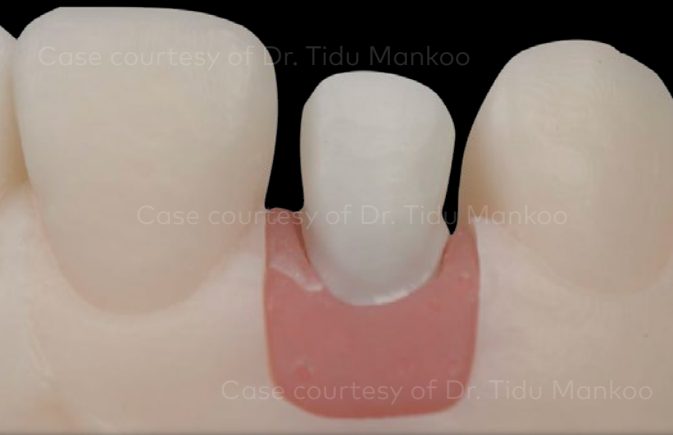Treatment planning



Restorative procedure



Outcome



DTX Studio™ Lab software was utilized to design the zirconia framework for a NobelProcera® ASC Full Contour Zirconia Implant Crown with labial cutback and veneered with porcelain on the labial side (work by Luc & Patrick Rutten).

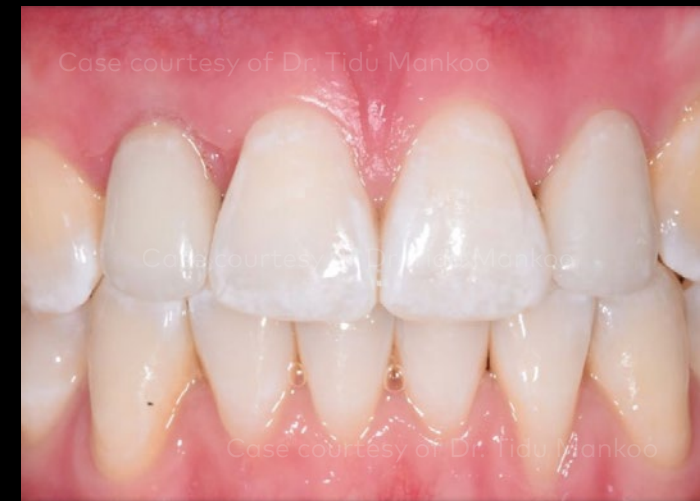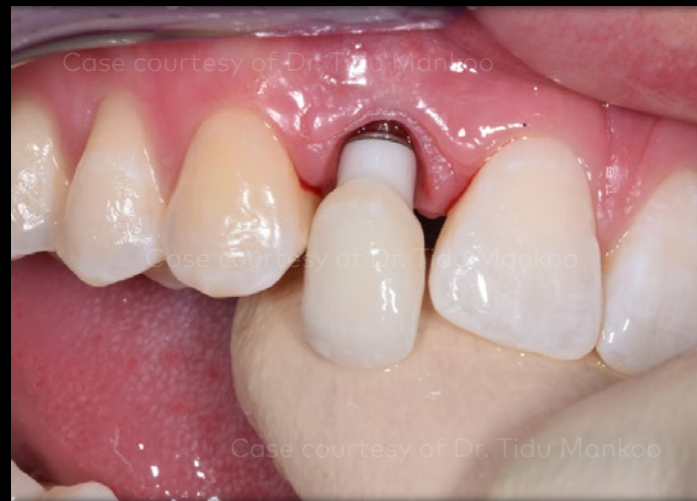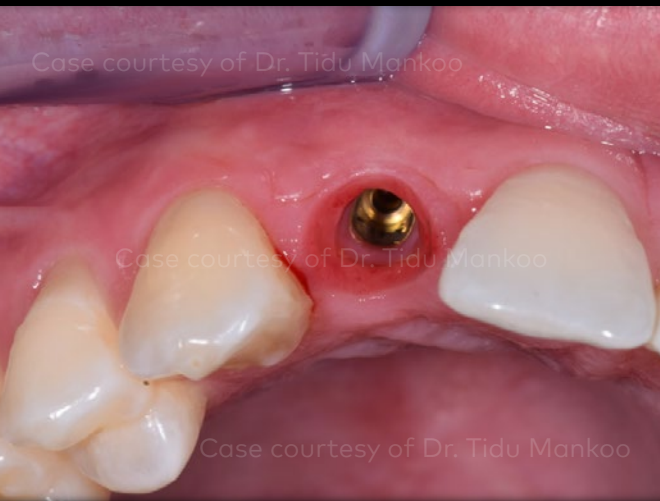Initial clinical situation

Treatment planning

Surgical procedure

Restorative procedure

Outcome



Delivery of the final prosthetic 3 months after the implant placement.

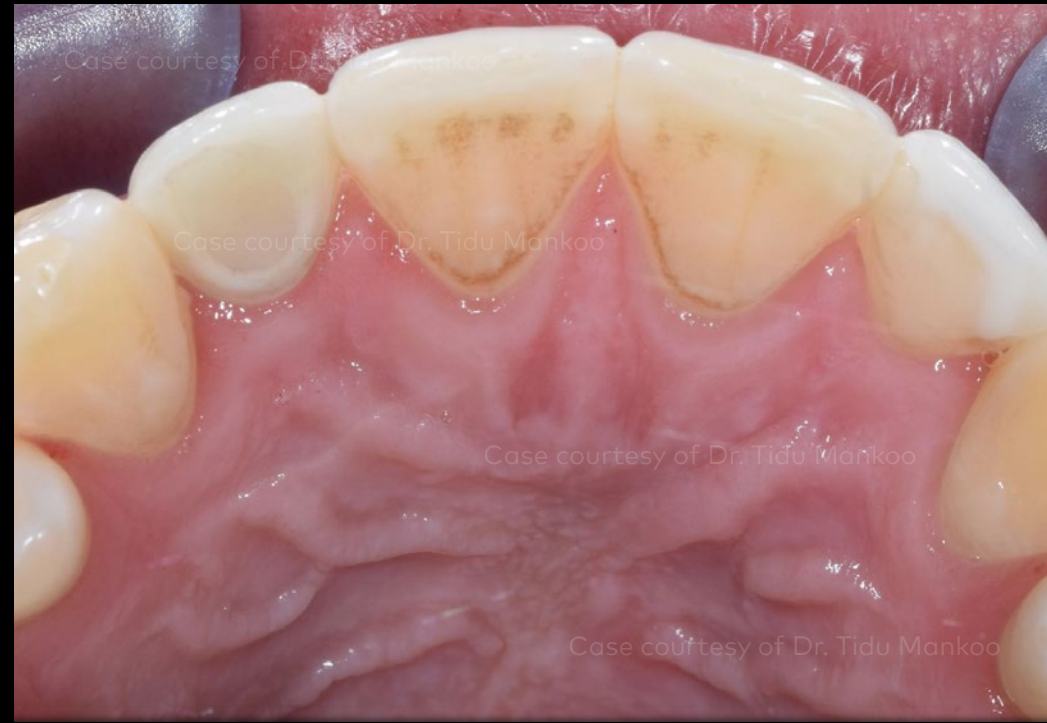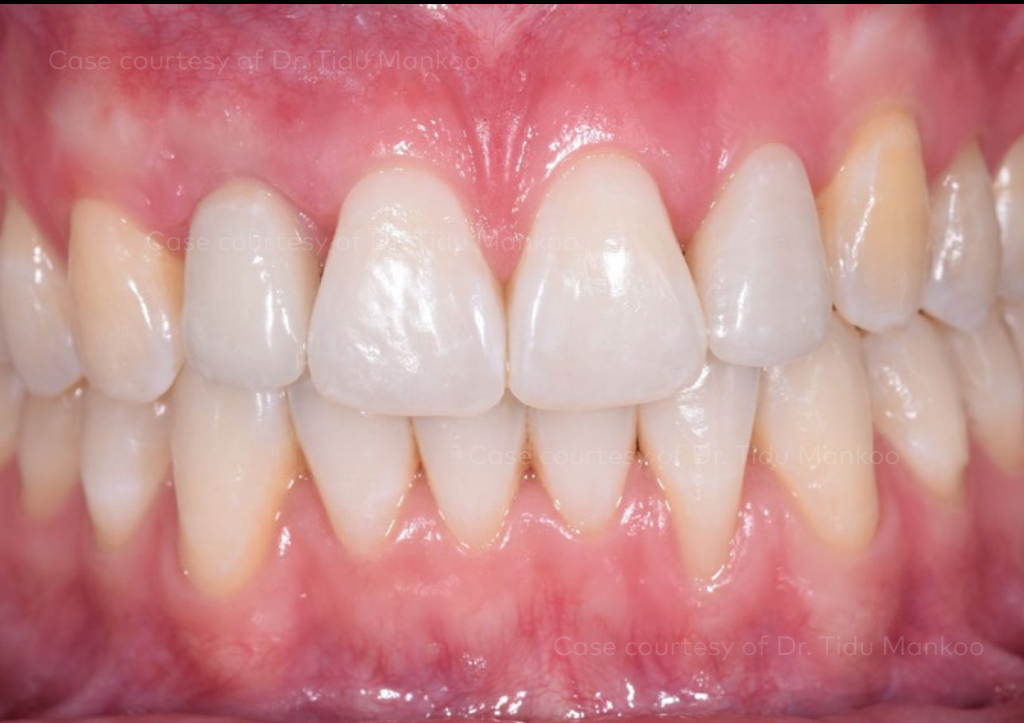Initial clinical situation

Treatment planning

Surgical procedure

Restorative procedure

Outcome



1 week follow-up: Intraoral view of the final restoration.

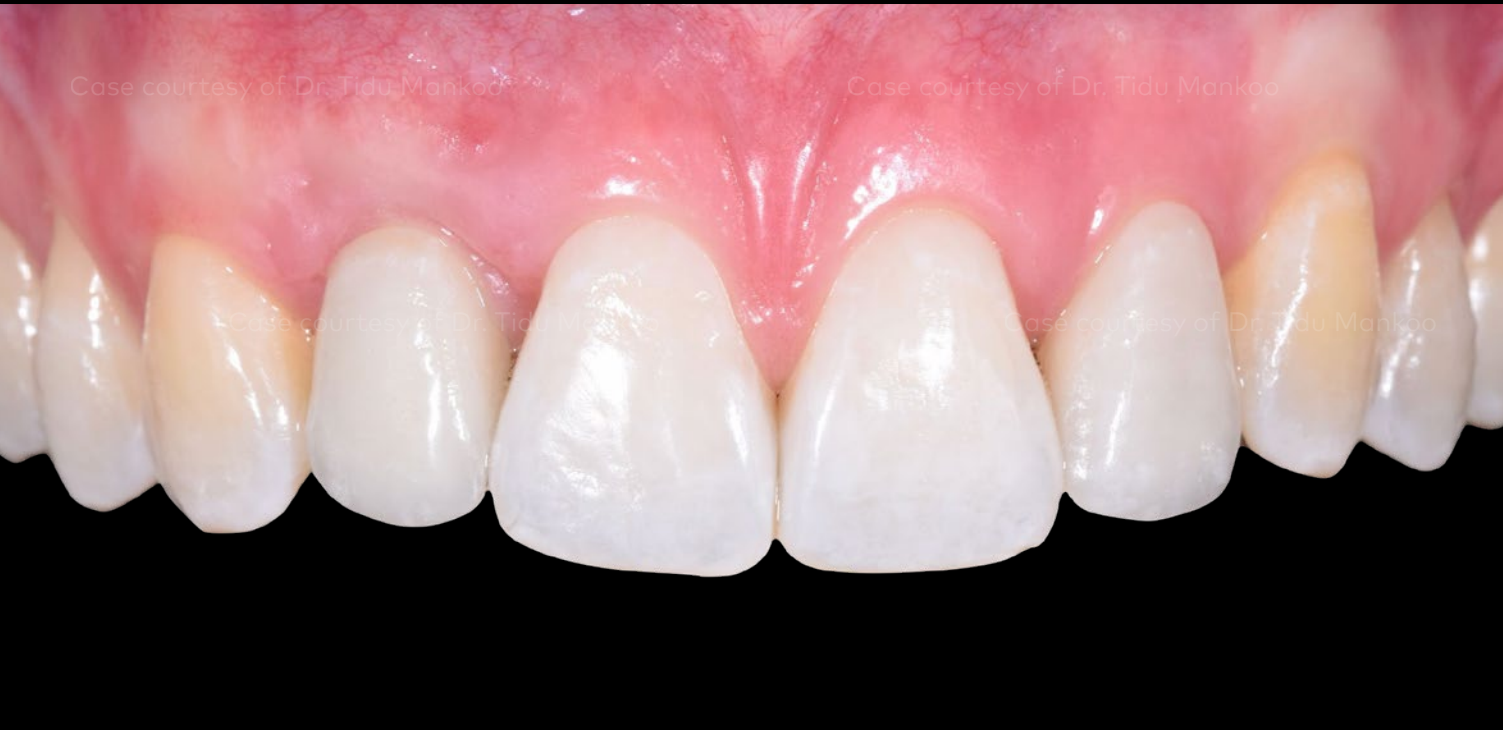Initial clinical situation

Treatment planning

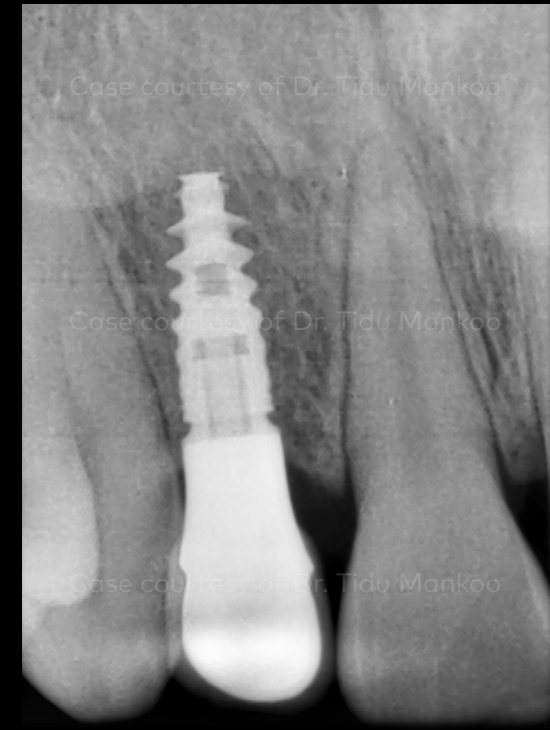Surgical procedure

Restorative procedure

Outcome



Clinical situation showing pleasing esthetic result after one month of follow-up.



Radiograph of the implant and the final prosthesis.

Case courtesy of Dr. Tidu Mankoo

